

A new stage of development of modern microscopy

Stepan Panov
MECOS company, Moscow, Russia
panovstepan@gmail.com

Abstract

Major achievements in the field of automation microscopy, such as automatic analysis of blood smear, counting leukocyte formula (wbc), automated analysis of feces for parasites, the creation of a virtual slide, online virtual slides are considered.

Machine vision applied to medical imaging, with high accuracy allow differentiating, and then segmenting the objects according to their typical properties.

The main problem is the difference in color and quality of the product depending on the method of its preparation and coating on a slide. To solve this problem applies a starting point for search algorithms and adapt to current conditions.

Keywords: *automated microscopy, virtual slides, virtual microscopes, blood analysis.*

1. INTRODUCTION

Image processing - an integral part of working with any kind of analysis and the results of medical research. History of medical imaging stems from the first electronic image of the musculoskeletal system, but we also look at the lab. Daily passes through a typical laboratory set a variety of tests ranging from blood and ending with a scrape on helminthes eggs. Any sample analyzed specialist based on their knowledge and experience. The accuracy and reliability of the results may cause some doubt in the absence of backup tests. Therefore, a new stage of development of laboratory tests is automated or robotic microscope, which allows you to automatically carry out the study, with follow-up inspection, adjustment and the ability to store the results.

2. ANALYSIS OF BLOOD SMEAR

Многие Many diseases can give the normal ratio of blood cells and abnormal cell morphology, so use only enough flow hematology analyzer. [3] Modern flow hematology analyzer can not detect unusual cells and approximately 20% of the test results are questionable. And there must be, at least, selective microscopic control results of flow hematology analyzer.[2] Microscopic examination is recommended for the differential diagnosis, particularly if the flow hematology analyzer has a deviation from the norm. Hand microscopy is labor-intensive and responsible work, requiring high stress. [4] The creation of an automated system can not only facilitate the work of specialists, but also to preserve the accuracy of detection of atypical cells.

Automatic analysis can be divided into several stages:

- Finding a starting point, the definition of layer thickness.

We move to the area of a monolayer of erythrocytes then we perform binarization of images and divide the objects and background, assessment of the size of objects

and their optical density in order to approach the values for the given values.

- Finding the cells.

The algorithm is based on the difference in color of the nucleus and other objects. The core is inherent in a blue color.

- Segmentation

At the end of the analysis it is necessary to determine the types of cells. The algorithm works as follows: Selecting the core. Isolation of the background. Separation of the remaining pixels in the cytoplasm and other objects.

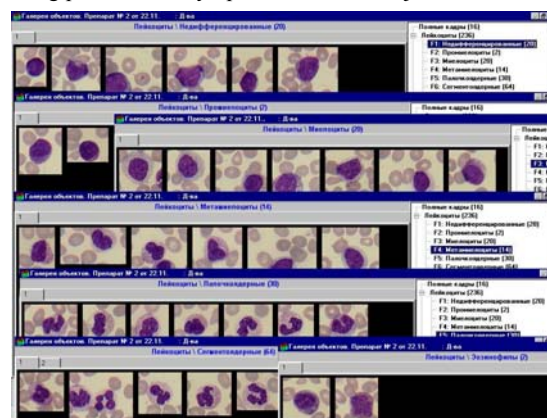


Image 1: Object gallery.

- Classification of erythrocytes.

Classification is carried out in form, size and optical density. Highlighted the atypical cells (echinocytes, drop-shaped, bite, eliptotsity, and irregularly shaped cells), macro- and microforms. Also allocated special types of cells with an abnormal profile of optical density (target cells, spherocytes, stomatotsity).

- Classification of leukocytes.

Six major types of cells are distinguished (stab neutrophils, segmented neutrophils, eosinophils, basophils, lymphocytes, monocytes). Color, luminance, geometric and textural characteristics are used.

3. ANALYSIS OF FECES FOR PARASITES

Another area of laboratory microscope is parasitology. In contrast to blood smears, to search for helminthes eggs it is necessary to examine the material at different focal lengths. Determination of the eggs carried by the characteristic black rings (shells). Sample preparation requires special attention to medications. In most cases, a complex station with a slide-camera, mounted directly on the object table of the microscope. Two variants of screening are possible:

- In the first case, the installation performs the screening, moving, and focusing the slide chamber on all area and depth, revealing helminthes eggs. Special holder for the slide chamber provides reliable attachment during rapid movements of automatic screening. Detected objects fall into a database for visual identification of the doctor on a computer screen. [1]
- In the second case, we create a digital 3D copy of the sample (virtual slide) and then analyze it in the workplace or remotely

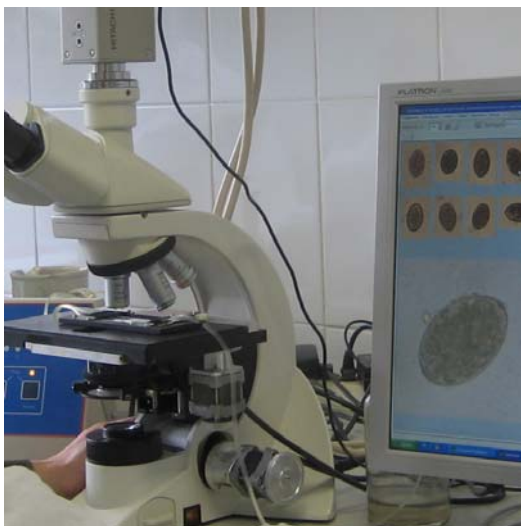


Image2: Automated analysis of the sample on helminthes eggs..

4. VIRTUAL MICROSCOPE

Virtual product is formed from a large number of neighboring primary physical field of view with an adaptive adjustment of the boundaries between them, one without defect border (pan).

Virtual drug can be viewed on a remote computer simulated microscopy (moving, different size) and morphometry of objects. Together with the virtual microscope, it became possible long-term storage of samples useful for quality control and training.

4.1 Virtual slides online

The development of Internet technology allows for the rapid exchange of information between laboratories. The integration of virtual slides with platform GMAPS API has significantly simplify remote research. On slides, placed on Internet site, you can navigate, edit, zoom, measure the dimensions of objects, as well as switch Z layers for 3D virtual slides of urine sediment, helminthes eggs and fecal matter. In contrast to real samples, virtual slides do not deteriorate over time and are available for viewing virtually for any interested man.

5. PROTECTION OF PERSONAL DATA

The generally accepted standard for transmitting medical images is a standard DICOM (Digital Imaging and COmmunications in Medicine). Storing the virtual slide is carried in several ways. The first option - stitched image (large image in JPEG2000 format, with a patient information). The alternative - a collection of sets

of tiles, numbered in order. In the case of placement of virtual slides on the Internet, patient information is not reported.

6. CONCLUSION

In conclusion, I want to note that the development of modern microscopy increases the accuracy and performance studies, which undoubtedly plays a crucial role in formulating the correct diagnosis.

7. REFERENCES

[1] Bogdan S. IV Bykov Parpar AA (CGE MBA MEKOS) Automated microscopy of fecal parasites.

[2] Cornet E., Perol J-P., X Troussard. Performance evaluation and relevance of the CellaVision™ DM96 system in routine analysis and in patients with malignant hematological diseases. Int J Lab Hematol. v.30, N 6, 2008.

[3] Honey, VS, AA Parpar Pyatnitsky AM, Sokolinskii BZ (MEKOS). Robotic microscopy introduces standard of quality blood smear analysis.

[4] Pyatnitsky AM, Honey VS Parpar AA (MEKOS) analysis of reticulocytes: manual microscopy, flow analyzers, analyzers or images?

About the author

Stepan Panov is a student at Bauman Moscow State Technical University, Faculty of special machines. He is an engineer at MECOS Company. His contact email is panovstepan@gmail.com